

LETTERS

Table. New leprosy cases detected among selected households, Oriximiná, Pará State, Brazilian Amazon, 2010*

Group	Household contact anti-PGL-I IgM ELISA result	No. households visited	No. persons examined	No. new cases		Total†
				Among persons previously tested	Among contacts of persons previously tested	
Leprosy patients	Positive	14	43	9	4	13
	Negative	11	42	1	1	2
Students	Positive	11	84	5	5	10
	Negative	8	53	1	4	5
Total		44	222	16	14	30

*Households were selected from among 35 leprosy patients encountered during the first visit (25 households, 14 with an anti-PGL-I-positive contact in the household and 11 without) and among students with results of anti-PGL-I serology (19 households, 11 with an anti-PGL-I-positive contact in the household and 8 without). PGL-I, phenolic glycolipid-I.

†Fisher exact test comparing case-patients and non-case-patients among those positive or negative for anti-PGL-I IgM revealed a statistically significant difference ($p = 0.0280$).

identifying new cases (7) and that such investigation must be conducted periodically. Our data also indicate that subclinical infections are highly prevalent among public school students in the Amazon region and that identifying students with positive anti-PGL-I test results can lead to discovery of new leprosy cases among students' household contacts.

Acknowledgments

We thank André Luiz Correa de Sousa, Márcia Leão, and Anna Elizabeth Martins Alves for collecting the samples and data from the patients; Sabrina Sampaio Bandeira for the patient impairment evaluation; Domingos Diniz, Miguel Canto, and the Programa de Ação Interdisciplinar at Oriximiná for logistical support and fruitful discussions; John Spencer for supplying the native PGL-I and technical support with the ELISA; the Oriximiná health secretary and community health agents; and the study participants.

C.G.S. designed and coordinated the study; clinically examined, diagnosed, and classified the subjects; statistically analyzed the data; and wrote the manuscript. D.V.G.F. collected and processed the samples, performed laboratory assays, and statistically analyzed the data. M.A.C.F. clinically examined, diagnosed leprosy, and classified the subjects. L.S.G. evaluated the functional statuses of the subjects. M.B.S. performed laboratory assays. J.G.B. designed the study and interviewed the participants. All authors participated in the interpretation of the data and read and approved the final manuscript.

This work was supported by the Conselho Nacional de Desenvolvimento Científico e Tecnológico (CNPQ: neglected diseases grant 576425/2008-7 and scholarship for C.G.S.), by the Secretaria Executiva de Saúde Pública do Estado do Pará and by the Universidade Federal do Pará.

**Claudio Guedes Salgado,
Denis Vieira Gomes Ferreira,
Marco Andrey Cipriani Frade,
Layana de Souza Guimarães,
Moisés Batista da Silva,
and Josafá Gonçalves Barreto**

Author affiliations: Federal University of Pará, Marituba, Brazil (C.G. Salgado, D.V.G. Ferreira, L.S. Guimarães, M.B. Silva, J.G. Barreto); Federal University of Pará, Belém, Brazil (C.G. Salgado, M.B. Silva); São Paulo University—Faculty of Medicine, São Paulo, Brazil (M.A.C. Frade); Dr Marcello Candia Reference Unit in Sanitary Dermatology of the State of Pará, Marituba (L.S. Guimarães); and Federal University of Pará, Castanhal, Brazil (J.G. Barreto).

DOI: <http://dx.doi.org/10.3201/eid1805.111018>

References

- Burki T. Old problems still mar fight against ancient disease. *Lancet*. 2009;373:287–8. [http://dx.doi.org/10.1016/S0140-6736\(09\)60083-0](http://dx.doi.org/10.1016/S0140-6736(09)60083-0)
- Moet FJ, Schuring RP, Pahan D, Oskam L, Richardus JH. The prevalence of previously undiagnosed leprosy in the general population of northwest Bangladesh. *PLoS Negl Trop Dis*. 2008;2:e198. <http://dx.doi.org/10.1371/journal.pntd.0000198>
- Penna G, Pinto L, Soranz D, Glatt R. High incidence of diseases endemic to the Amazon region of Brazil, 2001–2006. *Emerg Infect Dis*. 2009;15:626–32. <http://dx.doi.org/10.3201/eid1504.081329>
- World Health Organization. Leprosy update, 2011. *Wkly Epidemiol Rec*. 2011;86:389–99.
- Barreto JG, Guimarães LS, Leão MRN, Ferreira DVG, Lima RAA, Salgado CG. Anti-PGL-I seroepidemiology in leprosy cases: household contacts and school children from a hyperendemic municipality of the Brazilian Amazon. *Lepr Rev*. 2011;82:358–70.
- Moura RS, Calado KL, Oliveira ML, Bühler-Sékula S. Leprosy serology using PGL-I: a systematic review. *Rev Soc Bras Med Trop*. 2008;41(Suppl 2):11–8. <http://dx.doi.org/10.1590/S0037-86822008000700004>
- World Health Organization. Enhanced global strategy for further reducing the disease burden due to leprosy (plan period: 2011–2015). New Delhi (India): WHO Regional Office for South-East Asia; 2009.

Address for correspondence: Claudio Guedes Salgado, Laboratório de Dermato-Imunologia UEPA/UFPA/MC, Av João Paulo II, 113, Bairro Dom Aristides, CEP: 67200-000, Marituba, Pará, Brazil; email: csalgado@ufpa.br

Novel Prion Protein in BSE-affected Cattle, Switzerland

To the Editor: In a recent issue of *Emerging Infectious Diseases*, Seuberlich et al. (1) reported a novel prion protein in cattle with bovine spongiform encephalopathy (BSE). Two cows in Switzerland, 8 and 15 years of age, tested positive

in 2 approved screening tests, the PrioSTRIP test and the Prionics Check WESTERN (Prionics, Zurich, Switzerland). According to World Organisation for Animal Health guidelines, the 2 cattle are considered BSE positive. Histopathologic and immunohistochemical results were inconclusive because the tissues were severely autolyzed. Clinical signs were absent or the clinical history was not known.

After further analysis of brain tissues by using several monoclonal antibodies in a Western blot (WB), the authors concluded that they had identified an N-terminal truncated protease-resistant prion protein (PrP^{res}) fragment that differs from the PrP^{res} fragments in 3 known types of BSE. No reference was made to the existence of N-truncated fragments, such as C1, of the normal prion protein PrP^C, which have been reported for humans (2,3), mice (4), and cattle and other ruminants (5). The pattern in the WB of the novel prion protein (1) appears similar to that of the fragment C1 of the normal prion protein (2–5). The C1 fragment is more protease resistant than the intact PrP^C fragment because the protein part is more protected by the polysaccharide residues. Could it be that in the case of the severely autolyzed tissues of the cows in Switzerland, the proteinase K might already have been weakened or inhibited and when combined with the higher protease resistance of the C1 fragment, the digestion was incomplete?

Ten years ago, I looked at nonspecific, unusual samples from fallen stock cattle in New Zealand. Samples from these cattle had been confirmed as negative by paraffin-embedded tissue blot (University of Göttingen, Göttingen, Germany), sodium phosphotungstic acid precipitation, followed by WB (European Union Reference Laboratory for Transmissible Spongiform Encephalopathies, Veterinary

Laboratories Agency, New Haw, UK), Prionics WB (Prionics AG, Zurich, Switzerland), histopathologic examination, and immunohistochemical testing (Veterinary Laboratories Agency). We became aware of such samples when the proteinase K digestion did not work properly (Figure). Unusual samples 1 and 2 contained increased amounts of a truncated fragment of normal PrP^C, which was digested completely after the proteinase K concentration was increased.

I am convinced that the novel PrP^{res} described in the article by Seuberlich et al. (1) is indeed a truncated fragment of the normal bovine PrP^C protein. Therefore, I would like to ask the editor to address the following issues with the authors: Why were no references to truncated fragments of PrP^C made in their article? Why was no WB analysis performed in which the novel PrP^{res} was shown next to normal, undigested PrP^C for band-size comparison? Why were no WB analyses shown in which the proteinase K concentration was increased?

It is laudable that in vivo transmission studies using transgenic mouse models and cattle are under way, which will sort out these findings conclusively. I expect that no disease development will be shown. Meanwhile, announcing new types of BSE is purely speculation.

Reinhold Kittelberger

Author affiliation: Biosecurity New Zealand, Upper Hutt, New Zealand

DOI: <http://dx.doi.org/10.3201/eid1805.111824>

References

1. Seuberlich T, Gsponer M, Drögemüller C, Polak MP, McCutcheon S, Heim D, et al. Novel prion protein in BSE-affected cattle, Switzerland. *Emerg Infect Dis*. 2012;18:158–9. <http://dx.doi.org/10.3201/eid1801.111225>
2. Chen SG, Teplow DB, Parchi P, Teller JK, Gambetti P, Autilio-Gambetti L. Truncated forms of the human prion protein in normal brain and in prion diseases. *J Biol Chem*. 1995;270:19173–80. <http://dx.doi.org/10.1074/jbc.270.32.19173>
3. Pan T, Li R, Wong B-S, Liu T, Gambetti P, Sy M-S. Heterogeneity of normal prion protein in two-dimensional immunoblot: presence of various glycosylated and truncated forms. *J Neurochem*. 2002;81:1092–101. <http://dx.doi.org/10.1046/j.1471-4159.2002.00909.x>

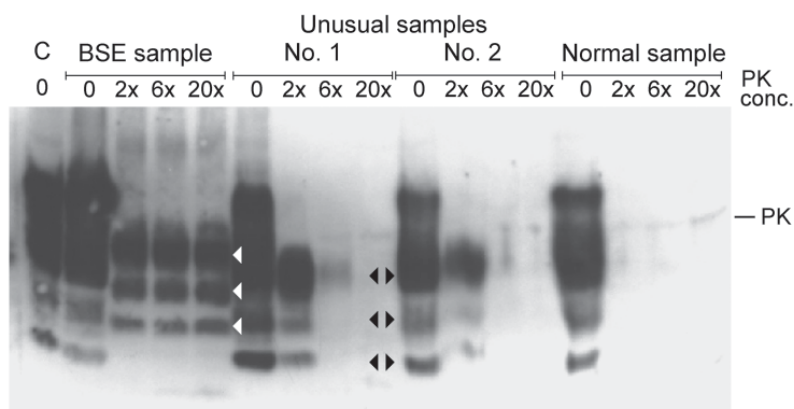


Figure. Western blot analysis of proteinase K (PK) digested brain stem samples with increasing concentrations of PK (relative to concentration used in the Prionics Check WESTERN (Prionics, Zurich, Switzerland)). C, kit control, normal bovine brain homogenate; BSE, bovine spongiform encephalopathy sample from cow from Switzerland; unusual samples 1 and 2 and normal sample are from New Zealand cattle and had been confirmed as negative by several test methods (see text). Unusual samples 1 and 2 show a higher concentration of a truncated fragment of the normal prion protein, which was completely digested at increased PK concentrations. It is typical for this fragment that bands are identical in size to lower bands of the normal prion protein in the undigested samples of normal brain homogenates (black arrowheads). White arrowheads show major bands of PK-digested BSE prion protein.

4. Mangé A, Béranger F, Peoc'h K, Onoder T, Frobert Y, Lehmann S. Alpha- and beta- cleavages of the amino-terminus of the cellular prion protein. *Biol Cell*. 2004;96:125–32. <http://dx.doi.org/10.1016/j.biolcel.2003.11.007>
5. Klingeborn M. The prion protein in normal cells and disease. Studies on the cellular processing of bovine PrP^C and molecular characterization of the Nor98 prion [dissertation]. Uppsala (Sweden): Swedish University of Agricultural Sciences; 2006.

Address for correspondence: Reinhold Kittelberger, Animal Health Laboratory, Investigation and Diagnostic Centre & Response, Biosecurity New Zealand, 66 Ward St, Upper Hutt 5018, New Zealand; email: reinhold.kittelberger@maf.govt.nz

In Response: Dr Kittelberger comments on our recent report of 2 cows in Switzerland that were classified as positive for bovine spongiform encephalopathy (BSE), according to the established criteria (1,2). He raises concerns that the unusual prion protein signature in Western blot (WB) in these cows represents a physiologic prion protein (PrP^C) fragment, inefficiently degraded by proteinase K (PK), termed C1. Certainly the effects of tissue autolysis on PK activity and the molecular prion protein signature are of particular concern and deserve full consideration in data interpretation. In our study, molecular mass comparisons between PrP^C in non-PK-treated brain tissue of healthy cattle and the prion protein in samples from the 2 aberrant cows with BSE in WB were considerably hindered by overlapping C1- and full-length PrP^C bands in the non-PK-

treated samples and did not allow for a robust conclusion (T. Seuberlich, unpub. data). It is noteworthy that the Prionics Check WESTERN (Prionics, Zurich, Switzerland) test has been extensively validated in terms of the diagnostic specificity, also on severely autolytic specimens (3–5). In none of these studies was a similar prion protein signature observed. We therefore considered it unlikely that the findings in the cases from Switzerland resulted from tissue autolysis.

Dr Kittelberger provides data from New Zealand cattle that revealed a similar prion protein signature in WB. He assumes that these animals had a negative BSE status and that the PK digestion in the WB did not work properly, which is supported by results from other diagnostic techniques. However, information about the degree of autolysis of these samples is missing, and, most notably, whether these findings are correlated with prion infectivity is not known. Strikingly, in contrast to the results for the samples from Switzerland, the samples from New Zealand are reported to be negative in the Prionics Check WESTERN. It would be fascinating to perform a side-by-side analysis of the samples from Switzerland and from New Zealand to determine whether the banding characteristics in both groups are identical. Studies are under way in our laboratory to further investigate the effect of tissue autolysis on PK activity and PrP^C degradation under experimental conditions. If our findings turn out to be the result of inhibited PK activity in BSE-negative cattle samples, the current diagnostic criteria might require revision. As long as the results of these experiments and

the ongoing transmission studies are not available, we can neither confirm nor reject a novel type of BSE.

Torsten Seuberlich

Author affiliation: University of Berne, Berne, Switzerland

DOI: <http://dx.doi.org/10.3201/eid1805.120226>

References

1. Seuberlich T, Gsponer M, Drögemüller C, Polak MP, McCutcheon S, Heim D, et al. Novel prion protein in BSE-affected cattle, Switzerland. *Emerg Infect Dis*. 2012;18:158–9. <http://dx.doi.org/10.3201/eid1801.111225>
2. Kittelberger R. Novel prion protein in BSE-affected cattle, Switzerland [letter]. *Emerg Infect Dis* 2012;18:890–2. <http://dx.doi.org/10.3201/eid1805.111824>
3. Schaller O, Fatzner R, Stack M, Clark J, Cooley W, Biffiger K, et al. Validation of a western immunoblotting procedure for bovine PrP(Sc) detection and its use as a rapid surveillance method for the diagnosis of bovine spongiform encephalopathy (BSE). *Acta Neuropathol*. 1999;98:437–43. <http://dx.doi.org/10.1007/s004010051106>
4. European Food Safety Authority. Scientific report on the evaluation of seven new rapid post mortem BSE tests. EFSA Scientific Report. 2004;18:1–13 [cited 2012 Mar 1]. <http://www.efsa.europa.eu/en/scdocs/doc/18r.pdf>
5. Office International des Epizooties. OIE procedure for validation and certification of diagnostic assays. Abstract sheet for the Prionics-AG Check WESTERN [cited 2012 Mar 1]. http://www.oie.int/fileadmin/Home/eng/Our_scientific_expertise/docs/pdf/Abstract_20sheet_OIE_20Register_PrionicsWB_v1.pdf

Address for correspondence: Torsten Seuberlich, NeuroCentre, National and OIE Reference Laboratories for BSE and Scrapie, University of Berne, Bremgartenstrasse 109a, CH- 3001 Berne, Switzerland; email: torsten.seuberlich@vetsuisse.unibe.ch

Correction, Vol. 18 No. 1

Author Henry J.C. de Vries' initials were listed incorrectly in Cutaneous Leishmaniasis Acquired in Jura, France (W.R. Faber et al.). The article has been corrected online (wwwnc.cdc.gov/eid/article/18/1/11-0408_article.htm).

DOI: <http://doi.dx.org/10.3201/eid1805.C11805>

Correction, Vol. 18 No. 2

Author Richard Njouom's surname was misspelled in High Seroprevalence of Enterovirus Infections in Apes and Old World Monkeys (H. Harvala et al.). The article has been corrected online (wwwnc.cdc.gov/eid/article/18/2/11-1363_article.htm).

DOI: <http://doi.dx.org/10.3201/eid1805.C21805>